

## PAROXYSMAL SUPRAVENTRICULAR TACHYCARDIA (PSVT)

Mary Boudreau Conover

*It is disappointing how many medical professionals are unable to make the diagnosis of PSVT and to differentiate between the two main causes, simply because they have not studied the mechanisms. This is about Sarah, who was seen and examined in an emergency tent while symptomatic during a triathlete competition and was never diagnosed! The point being, that a golden moment was missed when she was symptomatic because it is more difficult and sometimes impossible to make a definitive diagnosis with the ECG during sinus rhythm regarding the cause of PSVT unless there is an overt sign of pre-excitation.*

*For those reasons, this article is especially for the dedicated medical professionals who study hard and work smart under pressure during emergencies for better patient outcomes and for the medics who work in the emergency tents during athletic competitions. They can make a difference. They are Emergency Department Nurses and Physicians; Critical Care Nurses; Paramedic EMTs; and Fire Engine and Ladder Company personnel.*

### SARAH'S STORY

**Sarah Kerlin** is a national cyclocross champion, international competitor, trusting believer, and very lucky survivor who happened to be in the right locker room at the right time. For a chapter on “The Athlete’s ECG” in the 8th edition of my book, “Understanding Electrocardiography”, I wanted original electrocardiograms (ECGs) from some of the top athletes in our Santa Cruz community. Among them was Sarah, who graciously allowed me to record her there in the locker room before our swim workout. My expectation was that I would be recording the ECG of an elite athlete, nothing more. What showed up was much more – Wolff-Parkinson-White (WPW) syndrome, which, upon questioning her, turned out to be not only overt on the ECG, but dangerously symptomatic and life threatening. When asked if she had ever felt a sudden acceleration of her heart rate, known clinically as paroxysmal supraventricular tachycardia (PSVT). Her answer was a resounding and surprised-to-be-asked: “YES, every morning when I wake up and once during competition.” **Alarm bells!!** Should her PSVT convert to atrial fibrillation, her atria would no longer be pumping and her ventricular response would be over 200 to 300 bpm or more. She had no idea of the danger she was in! It took one phone call.

After that we moved quickly and urgently; a week later I drove her into UCSF for her appointment with Dr. Mel Scheinman, Director of Cardiology, took one look at the locker-room ECG, then he and his experienced crew of physicians threaded a catheter into Sarah’s heart, identified the accessory pathway, and delivered radiofrequency energy to heat up and destroy that tiny errant strand of cardiac muscle connecting atrium to ventricle. Just like that—diagnosed by ECG on the

UCSC locker room floor just before her usual 6 a.m. swim and cured two weeks later with an eloquent procedure in expert hands! Her alarming rapid heart rate wake-up call is now a faded memory. Sarah never hesitated nor doubted—just went ahead with what had to be done.

I can't say that Sarah was the only athlete I found with this congenital condition; there were four more and by that time my focus has changed from "The heart of a Santa Cruz Athlete" to "WPW syndrome in athletes"! In fairness to statistics, I need to say that I didn't find the other four; they found me. Having learned of Sarah's experience (SC paper), they recognized their own symptom of PSVT and asked me to record and evaluate their ECG.

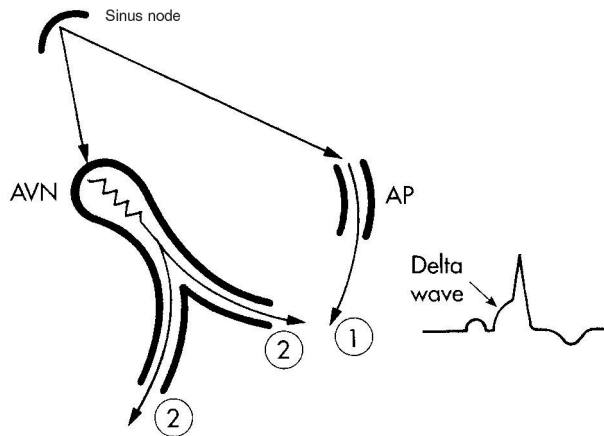
Now for the mechanisms of a sudden onset tachycardia that is NOT ventricular. For those readers who are not medically orientated, this information will help you to understand that sudden bursts and abrupt terminations of a very rapid rhythm is not the normal response of the sinus node.

## **PAROXYSMAL SUPRAVENTRICULAR TACHYCARDIA**

There are two main mechanisms of PSVT, AV nodal reentry (50%) and circus (circular) movement tachycardia (40%), sometimes called "AV reentry". AV nodal reentry tachycardia (AVNRT) is usually benign and can be terminated with a vagal maneuver, although sometimes it requires more aggressive treatment, such as ablation of the slow arm or its reentry circuit. Circus movement tachycardia (CMT) is seen in individuals with *Wolff-Parkinson-White (WPW) syndrome* and is potentially lethal because of the unexpected abnormal heart rhythms that can occur due to its anatomical substrate. Those arrhythmias are the subject of this article.

## **WOLFF-PARKINSON-WHITE (WPW) SYNDROME**

In WPW syndrome, there is an extra microscopic strand of muscle fibers, called an "accessory pathway" (AP), connecting an atrium to a ventricle. All muscle fibers conduct current rapidly---more rapidly than the atrioventricular (AV) node, the normal connection between the atria and the ventricles. During normal sinus rhythm, the impulse may enter the ventricles slightly early using the rapidly conducting AP (Fig. 1), which usually leaves a sign of early ventricular activation on the ECG known as a *delta wave*. The size of the delta wave can be anywhere from very tiny to very big when both ventricles are captured by the delta force, depending upon how soon that current arrives in the ventricle prior to activation across the AV node, its normal route. In Fig. 1 the sequence of activation is indicated. Note that even though the journey from the sinus node to the accessory pathway is longer than from the sinus node to the AV node, AP conduction is swift, producing a medium sized delta wave on the ECG. The delta wave is of course not a danger of itself. But, as you will see, the AP can cause big trouble when blocked.



**Fig. 1.** A diagrammatic representation of early activation of the left ventricle across an AP (1). The activation of the ventricles across the AVN (2) is a little slower, allowing the telltale delta wave to be seen. In some cases the delta wave can be very tiny, as in Sarah's case or it may not be seen at all (concealed WPW).

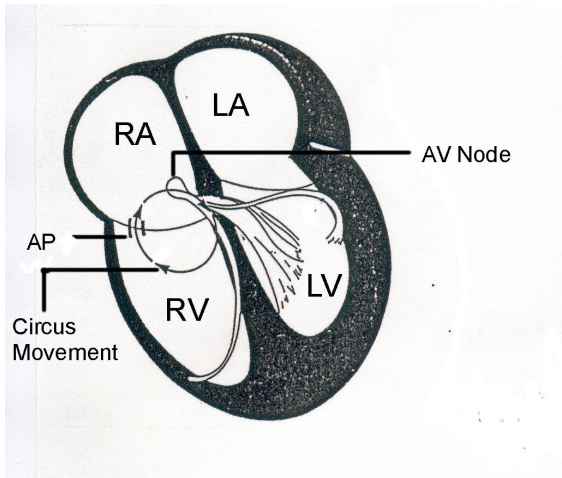
AP = accessory pathway; AVN = atrioventricular node

- 1) A normal sinus impulse (top) is shown penetrating the accessory pathway first, leaving no possibility for retrograde penetration from the ventricles once they are activated. The early activation of the ventricle is reflected by a delta wave on the ECG. Circus movement tachycardia does not develop in this milieu.
- 2) There is delay crossing the AV node so that activation of the ventricles across this normal pathway lags slightly behind the abnormal penetration.

It is also possible for the delta wave to be absent because of a latent or concealed AP. With the latent type, even with a normal ECG, the contribution of an accessory pathway in the production of PSVT or atrial fibrillation is still possible. The diagnosis is suspected by a well-informed examiner because of a history of PSVT and confirmed with electrophysiological testing. The term favored by many Electrophysiologists and Cardiologists for Wolff-Parkinson-White Syndrome is "Preexcitation Syndrome"---although not easily abbreviated, it is a far more accurate designation, with all due respect to Drs. Wolff, Parkinson, and White, who believed in 1930 that they were looking at bundle branch block---not the same<sup>1</sup>.

## **AN OVERVIEW OF MECHANISM**

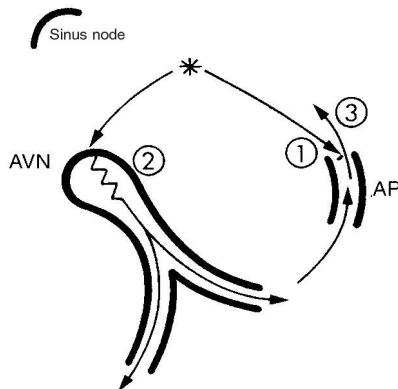
Circus movement tachycardia uses two pathways to complete a circle of excitation between the atria and the ventricles. In Fig. 2, the circuit is shown moving up the AP to the right atrium (RA) and down the AV node into the ventricles.



**Fig. 2.** A diagrammatic representation of the mechanism of circus movement tachycardia using a right-sided AP in the retrograde direction.  
 AP = accessory pathway; AV = atrioventricular

## STEP-BY-STEP

### The Beginning of Circus Movement Tachycardia

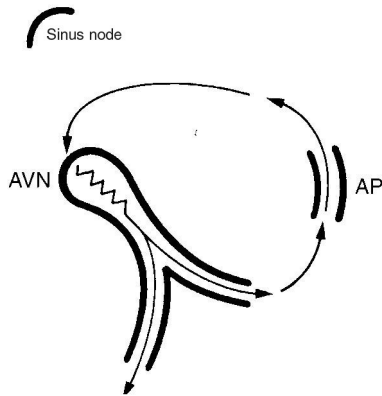


**Fig. 3.** Circus movement tachycardia usually begins with one errant (ectopic) atrial beat, indicated by the asterisk. The 1-2-3 events that follow are as indicated -- sequential.

- 1) The early atrial beat (\*) is blocked in a left-sided accessory pathway (AP).
- 2) The excitation wave enters the ventricles normally across the AV node.
- 3) The AP still has not been activated and is an open channel for retrograde penetration from the ventricles, setting the stage for a reentry circuit and PSVT. Note the reentry of the impulse into the atria at number 3.

Continue with Fig. 4 to see the next sequence when the impulse has dashed up the open AP and whips around to activate the AVN and start around again.

## The Maintenance of Circus Movement Tachycardia



**Fig. 4.** Around and around the current goes in this sequence:  
Atria→AV node→ventricles→accessory pathway→  
Atria→AV node→ventricles→accessory pathway→ etc etc etc --- PSVT!  
A reentry circuit thus established, continues until its path is interrupted, usually when a vagal maneuver slows or blocks conduction in the AV node.

### The Termination of Circus Movement Tachycardia.

In Fig. 4, draw an imaginary line across the AV node (AVN) where you see conduction slowing. This is what happens with a vagal maneuver---the circuit is interrupted and the sinus node will pick up its cadence once again---slowly at first because it has been suppressed.

### OBSERVABLE CHARACTERISTICS

**Heart rate.** Around 200 beats/min. (range 170-250).

**Heart rhythm.** Begins abruptly; maintains a regular rhythm; ends abruptly with a vagal maneuver.

**Frog sign.** During PSVT atria and ventricles are contracting simultaneously. The force generated by the ventricular contraction pushes blood up against the AV valves and shuts them tight. Thus, during atrial contraction the flow of blood normally destined for the ventricles is blocked by closed pressure-locked AV valves (mitral and tricuspid) and has nowhere to go but the wrong way--up. This causes a reflux up the jugular neck veins with every atrial contraction, causing the jugulars to bulge in time with the atrial contraction---fast and regular, like the regular puffing seen in a frog. This is a very visible sign and gives a leg up on ECG interpretation. Obesity precludes visibility of the jugular veins. It is important to understand that these pulsations in the jugular veins are regular in PSVT. Try vagal maneuvers; if that doesn't work, call 911.

**If the heart rate is rapid and there are only occasional pulsations (AV dissociation; VT) or no pulsations at all in the jugular vein, call 911 and have the AED ready.**

## **VAGAL MANEUVERS**

A vagal maneuver blocks the AV node, which is a critical choke point in the circuit just described. Vagal maneuvers create pressure in the pressor receptors (baroreceptors) located in several places in the body, but mainly in the aortic arch and carotid sinus. Sensing too much pressure, the message is sent to the brain, stimulating the vagus nerve. The effect is to slow conduction velocity in the AV node and interrupt the circuit, thus terminating the tachycardia. Some prehospital vagal maneuvers are:

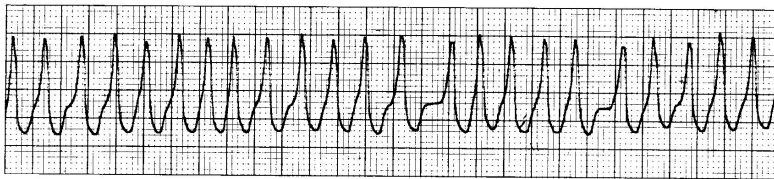
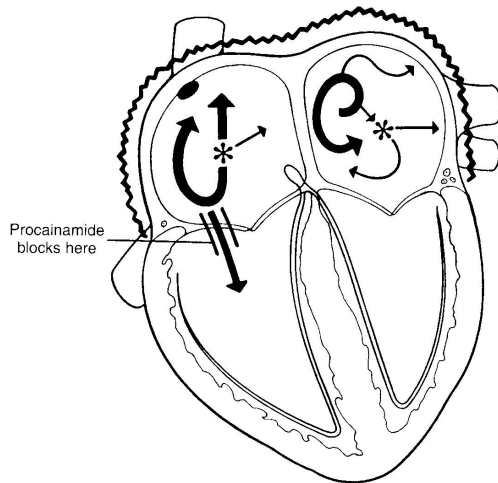
- Coughing (deeply)
- Straining
- Lying on the floor with legs elevated against the wall
- Blowing against a closed glottis
- Gagging (finger down the throat type)
- Rising from a deep squat

If one doesn't work, try another. Some people will not respond to the deep cough, but will convert to normal rhythm immediately when their legs are propped straight up. In the hospital setting, the physician will use carotid sinus massage, and for the very young, immersion of the face in cold water (the dive reflex). If the vagal maneuver stops the tachycardia, the person will usually feel OK and can carry on. However, they must see a Cardiologist and be cleared of any suspicion of overt or latent WPW syndrome.

## **POTENTIALLY LETHAL**

**Atrial fibrillation.** PSVT may result in atrial fibrillation, in which case many erratic electrical currents are causing the atria to quiver (fibrillate). When there is an accessory pathway offering a very rapid detour into the ventricles, the ventricular rate will be irregular and 200-300 beats/min. Atrial fibrillation can be lethal if it converts to ventricular fibrillation. When the atria are fibrillating and WPW syndrome is not present, the rate of the ventricles is controlled by a prescription medication. Thus, of itself, atrial fibrillation is not life threatening. It is a different story when there is an accessory pathway for rapid entry from an atrium into a ventricle---THAT is life threatening.

Even if one has never seen an ECG tracing before, the rapid (210 beats/min) irregular spikes in Fig. 5 would be alarming. Not all of these beats are felt at the peripheral pulse because the ventricles are not filling completely during each cycle. In spite of such a rapid heart rate and a reduced cardiac output, there are cases where a young, fit person with this arrhythmia drives to and walks into the ER. Having done so, the danger is that this rhythm will not be diagnosed soon enough or even correctly, and thus degenerate into ventricular fibrillation.



**Fig. 5.** Atrial Fibrillation in a Patient with Wolff-Parkinson-White Syndrome. In the atria there are multiple electrical currents, many of which pass rapidly down the accessory pathway to activate the ventricles. The accessory pathway needs to be blocked and there is one drug that is specific for that. Please refer to the references.

**Ominous physical signs of conversion to atrial fibrillation. 911 should already have been called and the AED made ready.**

There are three visible signs of conversion from PSVT to atrial fibrillation in cases of WPW syndrome.

- 1) The “frog sign” disappears---every time.
- 2) The hemodynamic condition worsens, i.e. the person may become unconscious, but this is not always the case.
- 3) The heart rhythm is irregular, although at such rapid rates this may be impossible to appreciate without an ECG recording.

**SUMMARY**

- Remember that sinus tachycardia is normal when physically active, frightened, or otherwise emotionally involved. It starts gradually and returns to normal gradually --- nothing sudden.
- Paroxysmal supraventricular tachycardia (PSVT) begins and ends abruptly.

- The diagnosis of PSVT can be made without an ECG because of the frog sign--a regular pulsing in the neck (jugular) veins similar to a puffing frog. However, the differential diagnosis between circus movement tachycardia and AV nodal reentry tachycardia is only made with multiple ECG leads by a medical professional who understands where the P waves are located in the two possible mechanisms.
- Remember that the regularity of the pulsing in the jugular veins is significant. **Fast and regular = PSVT. If there is irregular slow pulsing in the jugulars (VT with AV dissociation) or no pulsing (atrial fibrillation), call 911, stay with the victim, and have the AED ready.**
- PSVT can usually be stopped by a vagal maneuver.
- Atrial fibrillation in a person with an accessory pathway is potentially fatal. **Call 911; have the AED ready.** There is no frog sign in the neck veins. Vagal maneuvers do not help. There is a pulse, but it is very fast and irregular.
- If there is no pulse, defibrillate immediately. If no AED, start CCR. (see "What Happened to CPR")

### ECG RECOGNITION

If the patient is conscious, do not terminate the tachycardia before you record it. The ECG is your only shot at a differential diagnosis for this patient, possibly after many symptomatic years of undocumented bouts with PSVT.

- Quickly record a 12 lead ECG or at least I, II, III, and V<sub>1</sub>
- Check for P location, P axis, QRS alternans, and aberrant ventricular conduction---all are helpful in the differential diagnosis and are explained briefly below.<sup>2,3</sup>
- Jugular pulse: Frog sign = AVNRT or CMT; flutter waves = atrial flutter; irregular cannon A waves = VT.
- Try a vagal maneuver, which is diagnostic if it is atrial flutter (saw-tooth pattern seen); if it is PSVT it's therapeutic (stops the tachycardia.).
- If that doesn't work, follow your drug protocol, e.g.: adenosine, if that doesn't work—procainamide—if that doesn't work--cardiovert.<sup>2</sup>
- Record the sinus rhythm in the same leads for comparison (helps find Ps).



**P location.** In AVNRT the P distorts the end of the QRS (psuedo r in V<sub>1</sub> or psuedo s in inferior leads) or is completely hidden within the QRS. In CMT the P wave is *always* separate and usually closely follows the QRS (RP<PR). Whether you see a delta wave in the sinus rhythm tracings or not---this patient has an accessory pathway and should be admitted for evaluation for RF ablation.

**P axis.** Positive P waves in II, III, aVF indicate atrial tachycardia and rules out CMT and AVNRT. Negative P waves in II, III, aVF indicate AVNRT or CMT using a posterior septal AP. These are possibly the most useful ones.

**QRS alternans** (alternating heights of R peaks or depth of S nadirs) is a common occurrence (25-30% of the time) in CMT. Look for it first, examining all leads carefully. It is very uncommon to find this clue in AVNRT after the first few minutes.

**Aberrant ventricular conduction.** Aberrancy is more common in CMT than it is during AVNRT and is therefore helpful in the differential diagnosis.

**Jugular pulse.** Frog sign (fast regular expansion) = PSVT. Flutter waves = atrial flutter. Occasional cannon A waves during tachycardia = AV dissociation and is diagnostic for VT.

## **ATRIAL FIBRILLATION IN WPW SYNDROME**

- ECG: Fast, Broad, Irregular (FBI) Looks like VT except it is irregular; VT is usually regular. **Fast** because of rapidly occurring atrial impulses using a rapidly conducting AP; **Broad** because of ventricular activation outside the conduction system; **Irregular** because of atrial fibrillation and concealed conduction into the AV node and AP.
- If hemodynamically unstable, cardiovert.
- Do not use verapamil (danger of severe hemodynamic deterioration).
- Use procainamide. It prolongs the refractory period of the AP, the ventricles, and the retrograde fast AV nodal pathway. It may therefore slow conduction across the AP and the ventricular rate during atrial fibrillation. It may also terminate VT, CMT, and the common form of AVNRT.<sup>2,3</sup>
- If procainamide doesn't slow the ventricular rate, cardiovert.

## **ACKNOWLEDGEMENTS**

**Hein J.J. Wellens M.D.**, Professor of Cardiology at the University of Maastricht in the Netherlands and formerly Chairman of the Department of Cardiology at

University Hospital, Maastricht approved the section for ER personnel and EMTs. I would like to thank him for his continued support and encouragement.

**Heather MacDougall's (CFSC)** review and comments prompted me to add the step-by-step illustrations.

**Skip Hanson (CFSCC)** was encouraging with his review of the manuscript in its developmental stages.

The artwork is that of **Rene' Fontan**, West Hills, California.

**Elsevier Publishing Co.** holds the copyright on the illustrations.

## **REFERENCES**

1. Wolff L, Parkinson J, White P, et al: **Bundle-branch block with short P-R interval in healthy young people prone to paroxysmal tachycardia**, Am Heart J 5:685, 1930.
2. Wellens HJJ, Conover M: **The ECG in emergency decision making**, 2ed, Elsevier, 2006, St. Louis. pp 107 and 153.
3. Conover MB: **Understanding electrocardiography**, 8ed, Elsevier, 2003, St. Louis. pp. 275-300.

mc:Sept/2009